

Fibroma in the Tonsillar Region

Ashok L.

Abstract

Fibroma of tonsil is a very rare finding. True fibroma of tonsil is an uncommon benign neoplasm. Even in the reports of true fibroma of oral cavity, tonsillar fibroma is not often included due to its low incidence. As a result only a few case reports of such finding have been published. We are reporting a case of true fibroma of tonsil for its rarity.

Keywords: Benign Neoplasm; True Fibroma; Tonsil; Tonsillar Fibroma; Tonsillar Region.

Introduction

"There are comparatively few benign tumors of the tonsils, some types of these are so rare that each case is of great interest and worthy of being recorded" (Pearlman and Pilot, 1927 quoted by Lake et al., 1962).

Benign neoplasms of the tonsillar region are rare, and fibromas of the upper respiratory tract have been recorded in the nasal cavity, pharynx and larynx, buccal mucosa, tongue, palate and tonsil. Tonsillar tumors can be seen frequently as benign epithelial tumors, including papillomas, keratoacanthomas, and pleomorphic adenomas.

Those tumors of connective tissue origin include fibromas, schwannomas, lipomas, myxomas, chondromas, hemangiomas, and lymphangiomas. True fibromas of the oral cavity are rare, and to the best of our knowledge, there are few published reports of fibroma of the tonsil [1,2]. Fibromas are benign tumors that are composed of fibrous tissue and are very rarely seen in the oropharynx [2,4]. We describe a similar case of a fibroma of the tonsil.

Case Report

A 73yr old male patient reported to the OPD of Department of Oral medicine & Radiology, D.Y. Patil Dental

Author's Affiliation: Professor and Head, Dept. of Oral Medicine & Radiology, Bapuji Dental College and Hospital, Davangere.577004, Karnataka, India.

Reprints Requests: Ashok L., Professor and Head, Dept. of Oral Medicine & Radiology, Bapuji Dental College and Hospital, Davangere.577004, Karnataka, India.

E-mail: ashok_l2002@yahoo.co.in

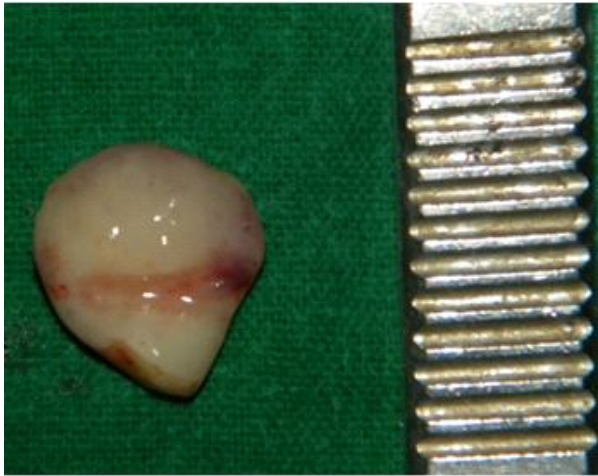
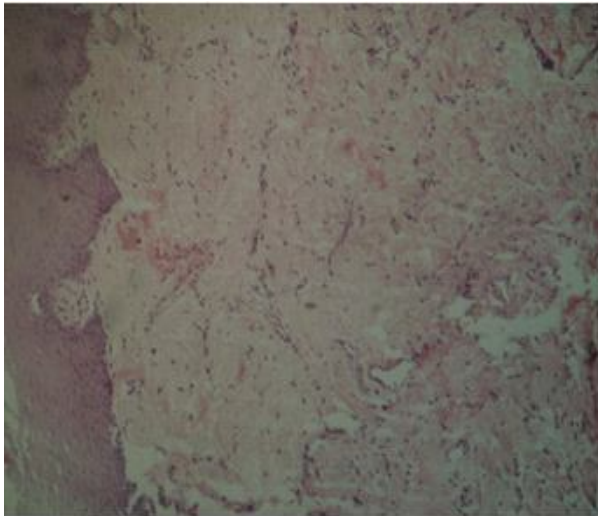
College & Hospital, Pimpri, Pune with a chief complaint of discomfort in the throat while swallowing since 2 days. Patient did not give any positive history of sore throat, dysphagia, fever, tonsillitis or change of voice. Patient also gave history of growth in the throat region since 50yrs. Past medical history of the patient was negative.

On examination a solitary soft tissue growth was seen on the right tonsillar area (Fig-1) which was pale pink in color, pedunculated & oval in shape. On palpation it was non-tender, smooth, mobile & firm in consistency measuring approximately 2.5cm x 1cm in size. Routine blood investigations were performed and all the results/values were within normal limits.

Excisional biopsy (Fig-2) was done under local anaesthesia & the specimen was sent for histopathological examination (Fig-3) which revealed the structure of fibroma. Patient was recalled after 1wk for the follow up (Fig-4).

Fig. 1: Preoperative photograph showing the growth in the right tonsillar area.

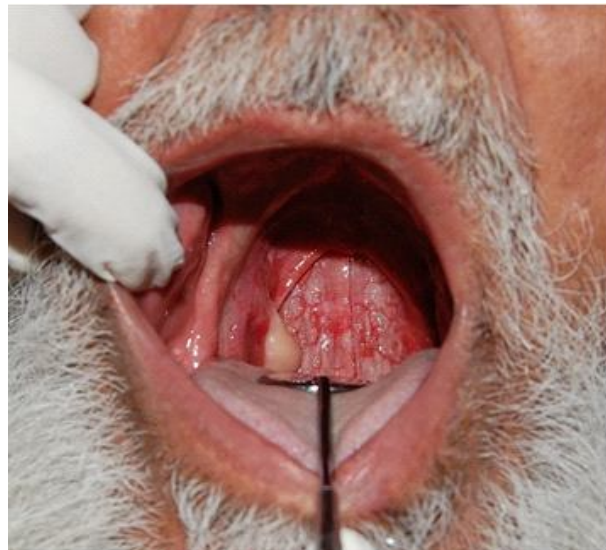

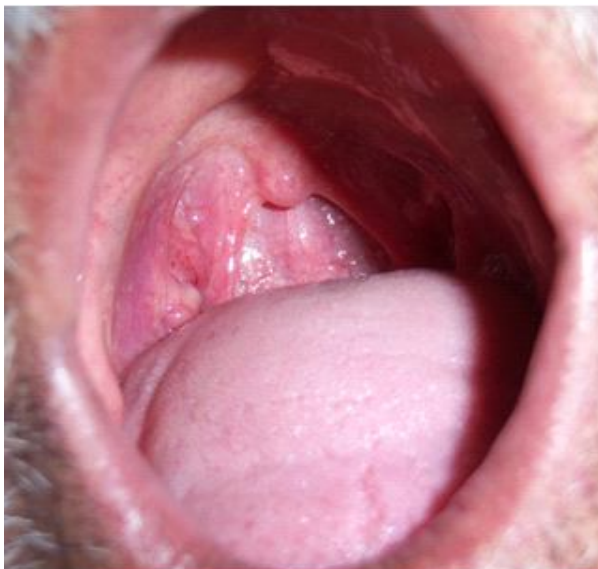Fig. 2: Gross specimen of the excised lesion**Fig. 3:** Shows stratified squamous epithelium with collagenous stroma.**Fig. 4:** Follow up after 1wk

Discussion

Fibroma of the tonsil is rare. New and Childry [5] in 1931 at the Mayo Clinic reported 63 cases of benign tumors of the tonsil and pharynx, which were observed from 1917 to 1930. Hara [6] in 1933 listed 26 cases, to which he added one to the literature. McKibben et al [7] in 1958 reported fibroma of tonsil as one of the rare tumors. Niccoli [8] reviewed 100 cases of benign tumours of the tonsil in 1956, out of which 70% were fibromas or fibroangiomas. C. Das in 1969[9], Goravalingappa JP, Mariyappa KC in 1999 [2] & Akdag. M in 2013 [10] have published case reports of fibroma of tonsil. Therefore the published reports from the long-term data regarding the fibroma of the tonsil appeared to be less.

The fibromas may be pedunculated or sessile. The pedunculated fibroma is commoner than the sessile type, as seen in our case. When well developed, it may easily be thrown forward on the tongue or partly swallowed at will. During sleep it may fall into the larynx and interfere with respiration [11]. Fibromas may vary greatly in size from a few millimeters in diameter to centimeters. They are smooth, rounded or oval, firm, elastic, pinkish white and covered with normal mucous membrane as seen in our case. Symptoms of these depend on their size and position. Most tonsillar fibromas are usually unilateral & originate from the superior pole of the tonsil [12] and extend inferiorly as seen in our case. If large enough, they may interfere with respiration. There may be irritation, odynophagia, foreign body sensation or slight soreness of throat and/or accompanied with cough, excessive salivation and abnormal nasal quality to voice. In our case there was discomfort while swallowing. They are usually asymptomatic in many cases and discovered accidentally during routine examination. If symptomatic, excise them as done in our case or perform tonsillectomies.

Conclusion

We are reporting this case as fibroma of tonsil is a very rare finding and to create awareness among the oral health care providers of such a very rare finding.

References

1. Friedmann I. Neoplasms of the tonsillar region. Systemic pathology, Churchill Livingstone. 1986; 173.

2. Goravalingappa JP, Mariyappa KC. Fibroma of tonsil. *Indian J Otolaryngol Head Neck Surg.* 1999 Jul; 51(3): 72-3. doi:10.1007/BF02996537
 3. Fu YS, Perzin KH. Nonepithelial tumors of the nasal cavity, paranasal sinuses, and nasopharynx. A clinicopathologic study. Fibrous tissue tumors (fibroma, fibromatosis, fibrosarcoma). *Cancer.* 1976; 37(6): 2912-28.
 4. Waal I and Snow G. B. *Otolaryngology Head and Neck Surgery.* Mosby Yearbook. 1993; 1238.
 5. New. G.B & Childry. J.H Tumors of the tonsil & Pharynx, *Archives of otolaryngology.* 1931; 14: 596-609.
 6. Hara. H.I Benign tumors of tonsil with special reference to fibroma. *Archives of otolaryngology.* 1933; 18: 63-68.
 7. Mckibben BG, Bozanic MS, Florez C. Benign fibroma of the tonsil; report of one case. *JAMA Arch Otolaryngol.* 1958; 67(1): 83-4.
 8. Niccoli Vallesi. R. *Boll. Mal. Orecche. Gola. Naso.*1956; 74: 176-78.
 9. Das, C. Fibroma of the tonsil. *Indian Journal of Otolaryngology.* 1969; 21: 133.
 10. Akdag M. Effects of Radiofrequency in a rare fibroma of the tonsil. *International journal of basic & clinical studies* 2013; 2(2): 118-121.
 11. BYRON G , Benign Fibroma of the Tonsil. Report of One Case, *AMA Arch Otolaryngol.* 1958; 67(1): 83-84.
 12. Taneja HC, Singh AP. Benign neoplasms of the tonsil. *Indian Journal of Otolaryngology and head and neck surgery.* 1998; 50(3): 287-290.
-